ResearchGate

See discussions, stats, and author profiles for this publication at: https://www.researchgate.net/publication/268080431

V–Y rotation advancement flap: A metanalysis and systematic review

Article *in* European Journal of Plastic Surgery · December 2014

DOI: 10.1007/s00238-014-1021-x

CITATIONS
7

READS
1,882

3 authors, including:

Utku Can Dölen
Saint Francis Hospital

36 PUBLICATIONS **246** CITATIONS

SEE PROFILE

All content following this page was uploaded by Utku Can Dölen on 28 February 2016.

The user has requested enhancement of the downloaded file.

Eur J Plast Surg (2014) 37:635–642
DOI 10.1007/s00238-014-1021-x

REVIEW

V-Y rotation advancement flap: A metanalysis and systematic review

Utku Can Dölen · Nezih Sungur · Uğur Koçer

Received: 7 July 2014 / Accepted: 14 September 2014 / Published online: 10 October 2014
© Springer-Verlag Berlin Heidelberg 2014

Abstract Local skin flaps are used to close defects adjacent to the donor site. They are classified according to their method of movement: flaps that advance from its base to the defect (V-Y, Y-V, single-pedicle, and bipedicle advancement flaps) and flaps that move on a pivot point (rotation, transposition, and interpolation flaps). Despite its frequent use, there is not a unique name for V-Y rotation advancement flap; moreover, there is not a flap class called "rotation advancement" in the textbooks. A systematic review of the literature was conducted using "PubMed" and "Google Scholar" in December 2013. We made different searches using keywords "V-Y-S flap," "V-Y rotation advancement flap," and "hatchet flap". The search was limited to the studies published in English and French. In total, 31 articles were found. Five articles presenting musculocutaneous hatchet flap, were excluded from the review. We included 26 articles in which cutaneous and fasciocutaneous flaps were described. We found 12 case series and five case reports presenting "hatchet flap." Two case series and two case reports about "V-Y-S flap" were reported. Four case series and one case report about "V-Y rotation and advancement flap" were written. V-Y rotation and advancement flap were performed under different names on any regions of the body by several authors, and none of the authors reported flap loss or any dehiscence that resulted with a second surgery. With the help of this review, we would like to standardize its design and its dissection.
Level of Evidence: Not ratable.

Keywords Local flap · V-Y-S flap · V-Y rotation advancement flap · Hatchet flap · Flap design · Cutaneous · Fasciacutaneous

U. C. Dölen (✉)
Dr. Abdurrahman Yurtaslan Ankara Oncology Training and Research Hospital, Plastic, Reconstructive and Aesthetic Surgery Clinic, Demetevler, Ankara, Turkey
e-mail: utkuchan@gmail.com

N. Sungur · U. Koçer
Ankara Training and Research Hospital, Plastic, Reconstructive and Aesthetic Surgery Clinic, Ankara, Turkey

Introduction

A number of wound closure techniques are available to the plastic surgeon. With the help of technology, our arsenal is now larger than ever. From simple dressing to nanotechnology, we have lots of new tools [1–4]. However, their price and the time needed to see the effects limit their usage.

Microsurgery, which turned the reconstructive ladder upside down, has a solution for any part of the body [5]. Even though it requires special microsurgical instruments and high experience, it is now generously performed in most of the hospitals [6]. However, in microsurgery, it is not always possible to close defects with similar texture and color. This is the point where the local flaps come to the stage for closure. Local skin flaps are used to close defects adjacent to the donor site. They are classified according to their method of movement: flaps that advance from its base to the defect (V-Y, Y-V, single-pedicle, and bipedicle advancement flaps) and flaps that move on a pivot point (rotation, transposition, and interpolation flaps) [7]. Despite its frequent use, there is not a flap class called "rotation advancement" in the textbooks.

In this article, we reviewed all the articles about V-Y-S flap, V-Y rotation advancement flap, and hatchet flap and wanted to standardize the design of the flap. In addition, we would like to present its adaptability in every part of the body.

Material and methods

A systematic review of the literature was conducted using "PubMed" and "Google Scholar" in December 2013. We made different searches using keywords "V-Y-S flap," "V-Y rotation advancement flap," and "hatchet flap." The search was limited to the studies published in English and French. The reference list of each retrieved article was manually searched to find other potentially relevant articles.

In total, 31 articles were found. Five articles presenting musculocutaneous hatchet flap were excluded from the review. We included 26 articles in which cutaneous and fasciocutaneous flaps were described. We found 12 case series and five case reports presenting hatchet flap. Two case series and two case reports about V-Y-S flap were reported. Four case series and one case report about V-Y rotation and advancement flap were written. There were no prospective cohort studies among these articles. All these retrospective articles were analyzed, and a qualitative meta-analysis was given in this article.

Results

History of the flap

V-Y-S plasty was first described by Argamaso in 1973 at the Annual Meeting of American Society for Aesthetic Plastic Surgery [8]. He used bilateral flaps to close the defect and the resultant scar, which was in "S" shape, gave its name to the flap. He wrote that that flap "adopts some aspects of the double rotation flaps (or S plasty) and so of the V-Y advancements for the closure of circular defects." Four years later, in 1977, Emmett published his clinic's 12-year-experience of using adjacent triangular flaps with subcutaneous pedicles to close the defects [9]. He mentioned that leaving a skin bridge in the pedicle produced a better-looking scar, broke the scar line, and also stabilized the subcutaneous pedicle. He called this unilateral flap "single triangular flap with a partially cutaneous pedicle" or generally known as "hatchet flap" because of its final scar. In addition, he called the bilateral flap "two triangular flaps with partially cutaneous pedicles" and referred to Argamaso's article that Argamaso named this flap "VYS flap."

In the literature, some authors followed Argamaso and called it VYS flap and other authors followed Emmett and called it hatchet or double hatchet flap (bilateral). In this review, we called this flap unilateral or bilateral V-Y rotation advancement flap (V-Y RAF) in order to standardize the language of the article.

Design of the flap

Argamaso started to design the flap by marking the lesion elliptically with the long axis parallel to the relaxed skin tension lines (RSTLs). Then the lesion, which was kept in the center of the ellipse, was excised and the triangular areas at the ends were left intact. Then, one side of a triangle was incised and a small back cut was made. The opposite side of the other triangle was incised and further flaps were rotated 45° and advanced toward each other in order to close the defect. He mentioned that undermining of the flap was not necessary if there was no difficulty on the mobility of the flap. Donor area was closed in V-Y fashion. The final suture line was in "S" shape.

Elliptical excision and direct closure use the elasticity of adjacent tissues, and it is only usable if there is excess tissue. However, if the defect is on a tight area where there is no spare skin, one can use the ends of the ellipse as local flaps. This is the idea that Emmett based the technique of triangular flaps with subcutaneous pedicles [9]. Contrary to Argamaso's design, he did not put the defect in the center of the ellipse because he was using unilateral flap. When necessary, a small triangle from the opposite side was excised in order to fit the scars into the RSTLs and also decrease the circumference of the defect. If it was needed, another small triangle could have been removed in order to prevent buckling where the pedicle turned. Unlike Argamaso, he preferred keeping the central subcutaneous tissue of the flap intact and as large as possible without compromising the movement of the flap. If greater mobility was needed, he did not hesitate to cut the skin of the pedicle. He used Z plasty to close the donor area of the flap where V-Y fashion closure could leave nondesirable scar or could not be achieved due to skin tightness. He wrote that in bilateral flaps, each flap had a lateral subcutaneous pedicle rather than a central pedicle (Fig. 1).

Elshahat used unilateral V-Y RAF on any part of the body [10]. He classified the hatchet flap into two types. Type I hatchet flaps had subcutaneous attachments (fascia or muscle) below the flap and its movement was dependent on the elasticity of the skin. However, it had dual blood supply, one from the perforators of deeper tissues and the other from the skin bridge of the pedicle. Type II hatchet flaps were completely free from the underlying tissues. Despite its higher mobility, the flap received blood supply only from the skin bridge of the pedicle (mainly subdermal plexus, known as random pattern). While describing the design of the flap, he did not mention the defect width to flap length ratio. Instead, he wrote that he did a V-shaped marking; one limb starting from the defect and the other stopped at a length of the defect radius. He added that the width of the pedicle was dependent on the circulation pattern of the flap and the location of the defect. He kept the pedicle narrower on type I flaps but larger on type II flaps and on extremities (equal to the defect diameter). In our opinion, type

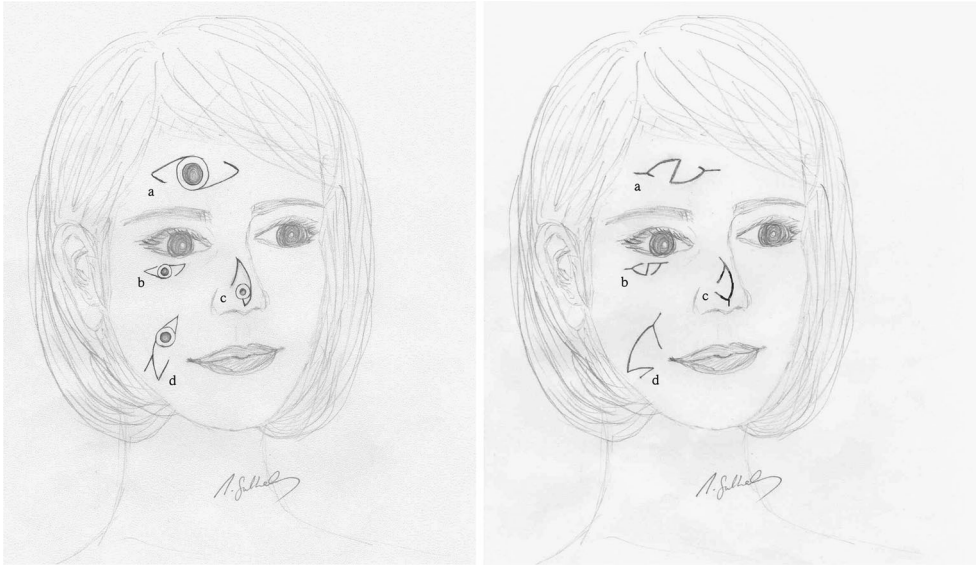

Fig. 1 Drawings of uni- and bilateral V-Y rotation and advancement flaps according to the Argamaso's and Emmett's articles. (*left*) Argamaso's bilateral flap design for a forehead defect (*a*). Both Argamaso's and Emmett's bilateral flap design for an infraorbital defect (*b*). Emmett's unilateral flap design for a nasal defect (*c*). Emmett's unilateral flap design for a buccal defect and closure of the donor area with Z plasty (*d*). Emmett preferred to excise a small triangle on the opposite site of the unilateral flap to obtain a smooth scar line. (*right*) Final scars of the flaps

I flaps look like Emmett's design and type II flaps resemble Argamaso's design.

Abd El-Rahim and Kamal used unilateral and bilateral to correct acquired alopecia. They defined the following equation for bilateral V-Y RAF: 4×(the alopecia width)+2=the sum of both limbs of the V-Y-S flaps [11].

Demir et al. used bilateral V-Y RAF for scalp reconstructions. They draw triangles with a base equal to the width of the defect and the long axis of the triangles was about two times longer than the base [12].

Gurunluoglu et al. reconstructed forehead and infraorbital defects with bilateral V-Y RAF. In their design, flaps had the same width with the defect and the width to length ratio of the flap was 1:1.5 [13, 14].

Fernández-Calderón et al. repaired scalp defects with bilateral V-Y RAF. In their design, the length of the flap was approximately 1.5 times longer than the diameter of the defect and the width of the skin pedicle was equivalent to the radius of the defect [15].

Sheridan and Humzah, marked the lesion elliptically and planned bilateral V-Y RAF as Argamaso described [16]. They did not give any equation for the design but they said that the back cut was made 30–50 % of the remaining side. They recommended not to exceed 50 % in order not to compromise flap viability, especially at the tip. Even though Argamosa did not mention the exact length of the back cut, he emphasized "small" to warn against those devastating complications. They called that closure "dollar plasty" regarding the final shape of the suture line.

Zhi-guo et al. used unilateral V-Y RAF to reconstruct cheek defects. They indicated that the ratio of pedicle width to the length of the flap incision ranged between 1:2 and 1:3 [17].

Borman and Maral closed sacral decubitus ulcers with uni- and bilateral V-Y RAF. In their design, the length of the flap was equal to the diameter of the defect [18].

Sowerby et al. excised 483 cutaneous malignant neoplasms from all over the body and closed the defects with bilateral V-Y RAF [19]. Figure 2 explains their different design.

In our previous study, we used uni- and bilateral cutaneous V-Y RAF in almost every part of the body. The following equation for unilateral V-Y RAF was defined: the distance between the center of the defect and the flap corner is two times longer than the diameter of the defect. For bilateral V-Y RAF this distance is 1.5 times longer than the diameter of the defect [20].

In order to clarify the flap design, we updated our previous design and enhanced it with figures (Figs. 3 and 4). The length of the unilateral V-Y RAF is equal to three times horizontal radius of the defect ($a-b=3r$). The length of the bilateral V-Y RAF is equal to twice

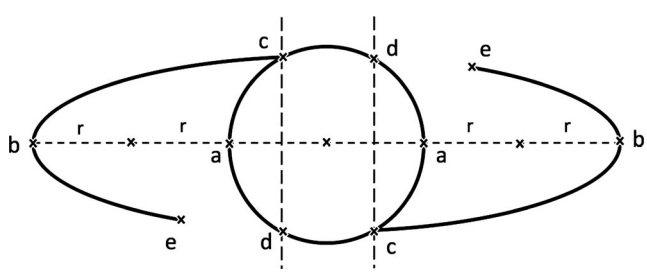

Fig. 2 Sowerby et al.'s bilateral flap design. Points *a* are the intersection between the *circle* (defect) and the *horizontal line* dividing the circle into equal halves. The length of the flap equals the distance between the flap corner (*b*) and the point (*a*). They described that the length of the flap was equal to the diameter of the defect. The limb of the flap was connected to point (*d*), which is the intersection of the thirds and the *circle*. The width of the skin pedicle equaled to the radius of the defect (distance $e-d=r$)

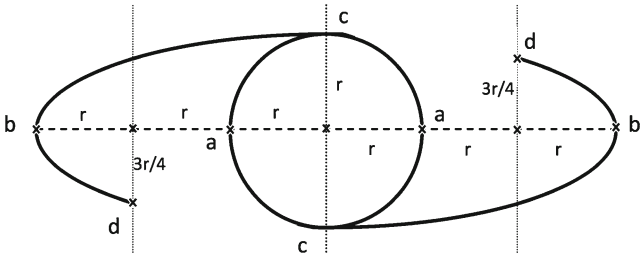

Fig. 3 Our bilateral flap design. Longer limb of the flap connects to the point (*c*), which is the intersection between the *circle* and the *line* dividing the circle into two equal halves. The distance between the corner of the flap (*b*) and the projection of the most distal part of the back cut (*d*) onto the *horizontal line* equals to the radius (*r*) of the circle (defect). The length of the flap is equal to twice of radius (distance $a-b=2r$)

of radius ($a-b=2r$). These formulas can be changed if the horizontal and vertical diameters are not equal to each other. If the flap is planned horizontally, horizontal radius is used for the equation as well as vertical radius for the vertically planned flap.

The designs described by different authors are approximately similar to each other and the length of flap equals at least the diameter of the defect in both unilateral and bilateral V-Y flap. There is no consensus on the length of the back cut, but it is recommended by many authors to keep it long enough to increase the mobility of the flap but short enough not to risk flap viability.

Advancement of the flap equals the length of the skin closed by V-Y fashion. By making the angle of the flap's corner more acute, primary closure can be facilitated and dog-ear formation can be prevented. The rotation movement of the flap is 45° at maximum because of the tension of the pedicle [8, 16]. It is always wise to plan the flap slightly concave at the corner in order to facilitate primary closure and plan the rest slightly convex to include all the cutaneous perforating vessels [18]. The defect that occurs after the advancement is closed primarily (V-Y fashion). By making the angle of the flap's corner more acute, primary closure can be facilitated and dog-ear formation can be prevented. Case series with more than five patients were put in a table in chronological order (Table 1).

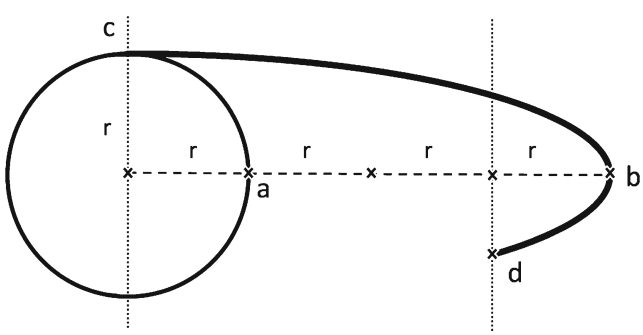

Fig. 4 Our unilateral flap design. The length of the flap is equal to three times horizontal radius of the defect (distance $a-b=3r$). Back cut can be lengthened to increase the mobility of the flap

Reconstructed body parts and the dissection plan of the flap

Scalp

In scalp reconstruction, flaps were elevated in the subgaleal plane [10, 12, 15, 20]. Abd El-Rahim and Kamal also used the same plane for alopecia reconstruction with uni- or bilateral V-Y RAF [11]. It is also recommended by authors to do incisions parallel to the direction of hair follicles not to cause scatricial alopecia and if possible, include one of the dominant arteries of scalp to the flap. Despite their high number of patients with 212 scalp reconstructions, Sowerby et al. did not describe their surgical plane [19].

Face

Argamaso used this flap to cover facial defects and he emphasized that V-Y RAF cause less displacement of the adjacent tissues and therefore asymmetry of the paired structures (oral commissure, eyelids, etc.) is less likely to happen [8]. Emmett planned the incisions according to the RSTLs and pointed out that leaving a skin bridge in the pedicle resulted with a better-looking scar [9].

On the face, flaps are elevated superficial to the superficial muscular aponeurotic system (SMAS). Sharma et al. reconstructed a defect measuring 12×9.5 cm on the cheek with multiple V-Y RAF [28]. Zhi-guo et al. operated 29 patients who had cheek defects [17].

Gurunluoglu et al. elevated bilateral V-Y RAF above the SMAS and the frontal muscle to cover supra-eyebrow defects. They placed the incisions with respect to the RSTLs and the contour line of the eyebrow. They did a meticulous dissection to protect the supraorbital and supratrochlear nerves [13]. Sungur et al. went deeper and included the frontal muscle into the flap by dissecting above the pericranium to cover a gunshot defect on the forehead [20].

Baron et al. reported their experience of unilateral V-Y RAF on lateral facial region of five patients. They placed the pedicle of their flaps on the pre-auricular region and on the anterior part of the parotid region where cutaneous perforators were concentrated [26].

Reynaud reconstructed nasal defects of 30 patients with unilateral V-Y RAF. He undermined the flap completely and excised a small triangle adjacent to the defect in order to insert the tip of the flap [27]. Larger flaps can be planned by placing the back cut to the glabellar area [29]. Flap is elevated superficial to the perichondrium and periosteum of the nose. In the glabellar area, the dissection plan can be either superficial or deep to the procerus muscle [20, 29]. The left or right trochlear artery can be kept inside the base of the flap in order to

Table 1 Table showing the case series with more than five patients

First author	Year	Country	Name of flap used in the article	Flap type	Location	Cause of the defect	Anesthesia	Number of patients	Number of flaps	Mean age of patients (years)	Size of the defects (cm)	Size of the flaps (cm)	Drains	Follow-up (months)	Complications
Lane [21]	2013	UK	Hatchet	Unilateral	Forearm	Donor area of radial forearm free flap	–	45	45	54 (range 38–71)	Length 3.5–6.5 (mean, 4.7); width 5.5–11 (mean, 7.6)	–	–	6–100 (mean, 43.7)	None
Sungur [20]	2013	Turkey	V-Y Rotation and Advancement	Uni-/Bilateral	All regions of the body	Any	Local and General	68	98	50 (range, 19–84)	2×2–26×16 (mean, 7×4)	–	Yes	7–21 (mean, 13)	None
Abd El-Rahim [11]	2012	Egypt	V-Y-C and V-Y-S plasties	Uni- /Bilateral	Scalp	Alopecia	–	20	29	19 (range, 4–30)	Length, 3.5–6.5; width, 3–6	–	Yes	6–12	1 superficial distal sloughing
Elshahat [10]	2012	Egypt	Hatchet	Unilateral	All regions of the body	Any	–	40	46	44.7 (range, 1–67)	–	–	Yes	Mean, 6.6	3 partial dehiscences
Fernandez-Calderon [15]	2012	Spain	Hatchet	Bilateral	Scalp	Excision of cutaneous malignant lesion	–	20	40	76	3×3–7×7 (mean, 4)	–	Yes	–	None
Gurunluoglu [13]	2012	USA–Switzerland	Hatchet	Bilateral	Supra-eyebrow and forehead	Excision of cutaneous malignant lesion	Local and General	10	20	–	2.5×2.5–3.5×3.5	–	–	6–36 (mean, 13.5)	None
Kuwahara [22]	2012	Japan	Hatchet	Unilateral	Upper lip	Excision of cutaneous lesion	–	6	6	Range, 24–92	1.2×1.2–2.4×2.5	–	–	–	3 trap door deformities
Sungur [23]	2012	Turkey	V-Y Rotation and Advancement	Bilateral	Fingertip	Trauma	Local	7	14	37.6 (range, 21–65)	1×0.4–2×1	1×0.5–1.8×0.9	–	3–24 (mean, 18)	None
Zhi-guo [17]	2012	China	Hatchet	Unilateral	Cheek	Excision of cutaneous lesion	Local	29	29	Range, 19–81	1.5×1.5–2.5×3.5	–	–	12–18 (mean, 14)	None
Gurunluoglu [14]	2012	USA	Hatchet	Bilateral	Lower eyelid and infraorbital skin	Excision of cutaneous lesion and trauma	Local and general	25	50		1.1×1.1–1.5×1.5	–	–	6–24 (mean, 13.7)	None
Sowerby [19]	2010	Canada	Double hatchet	Bilateral	All regions of the body	Excision of cutaneous malignant lesion	–	483	966	–	–	–	–	–	1 dehiscence, 1 distal tip necrosis, and 1 hypertrophic scar
Sungur [24]	2006	Turkey	V-Y rotation and advancement	Unilateral	Sacrococcygeal area	Pilonidal sinus	–	8	8	34.28	–	Length, 9–18; width, 6–12	Yes	7–12 (mean, 18)	2 superficial infections and 1 partial dehiscence
Tuncali [25]	2006	Turkey	Hatchet	Unilateral	Fingertip	Trauma	–	9	9	3.1 (range, 19–43)	1.2×0.5–2.8×2.4 (mean, 2.1×1.5)	–	–	Mean, 12	2 cold intolerances and 1 partial dehiscence
Demir [12]	2003	Turkey	V-Y-S Plasty	Bilateral	Scalp	Tumor excision, burn, and alopecia	Local and general	22	44	49 (range, 28–72)	3.5×4–6×6.5 (mean, 4.5×5)	–	–	6–60	None
Borman [18]	2002	Turkey	V-Y rotation and advancement	Uni-/bilateral	Sacrococcygeal area	Decubitus ulcer	–	15	15	48.2 (range, 34–84)	4×4–18×12 (mean, 9.3) and 10×10–18×18 (mean, 13.7)	–	Yes	1.5–35	None
Baron [26]	1990	France	Hatchet	Unilateral	Lateral region of the face		–	5	5	–	–	–	–	–	–

Table 1 (continued)

First author	Year	Country	Name of flap used in the article	Flap type	Location	Cause of the defect	Anesthesia	Number of patients	Number of flaps	Mean age of patients (years)	Size of the defects (cm)	Size of the flaps (cm)	Drains	Follow-up (months)	Complications
						Excision of malignant lesion									
Reynaud [27]	1983	France	Hatchet	Unilateral	Nose	Excision of cutaneous lesion	–	30	30	–	0.6×0.6–2.5 (mean, 1.35)	–	–	–	1 partial necrosis

increase the blood supply. In the remodeling period, this flap pulls the tip of the nose and cause upward tip rotation that must be explained to the patient before the surgery.

Pan et al. used unilateral V-Y RAF in defects of upper and lower eyelid and nasal ala. They planned their flaps superficial to the subcutaneous tissue with the subdermal plexus intact [30]. By contrast, Gurunluoglu et al. elevated bilateral V-Y RAF above the orbicularis oculi to cover lower eyelid defects [14].

Kuwahara et al. reconstructed the skin and vermillion defects of upper lip with unilateral V-Y RAF on six patients. They placed the suture line on the nasolabial fold to disguise the scar. They dissected the flap above the orbicularis oris muscle in the upper lip area and the same thickness as the upper lip flap in the cheek area [22].

Makiguchi et al. reported a case report where they covered an 80 % defect of the lower lip with multiple unilateral V-Y RAF and nasolabial advancement flap. In their design, the vertical length of the defect was nearly the same as that of the skin flap [31].

Yu et al. presented a case report where they reconstructed a defect with a diameter of 1.5 cm on the helical rim of the ear. They planned bilateral V-Y RAF extending along the whole length of the helix and did the dissection above the perichondrium [32]. Head-neck reconstruction was performed on 6 patients by Elshahat and on 154 patients by Sowerby [10, 19].

Body

Abdominal defects were covered with unilateral V-Y RAF, which was elevated superficial to the fascia of the rectus abdominis muscle [20].

Elshahat closed the defects of the chest, axilla, lumbosacral region, buttock, scrotum, perineum, and vulva with unilateral V-Y RAF. He elevated those flaps on the subfascial plane [10].

Borman and Maral reconstructed 15 sacral decubitus ulcers with uni- and bilateral V-Y RAF, and they harvested the flap above the gluteus muscle [18]. Sungur et al. used the same fasciocutaneous flap for the same reason [20] and in addition, for the excisional defects of sacral pilonidal sinus [24].

Extremity

Lane et al. covered the donor site of the radial forearm free flap with unilateral V-Y RAF on 45 patients [21].

Schwabegger et al. published a case report in which they covered a shoulder pressure sore (diameter, 5 cm) with unilateral V-Y RAF. They elevated the flap above the deltoid muscle and designed the skin pedicle on the posterior part in order to include neurovascular bundle [33].

Sungur et al. reconstructed eight trochanteric ulcers with unilateral V-Y RAF elevated superficial to the fascia of the muscles. They reconstructed four knee defects with bilateral V-Y RAF elevated above the patellar tendon. They covered

two tibial defects with bilateral and three heel defects with unilateral V-Y RAF elevated above the periosteum. They also covered four dorsal hand defects with unilateral V-Y RAF harvested superficial to the paratenon of extensor tendons [20].

Tuncali et al. published their study about the reconstruction of nine fingertip amputations. They used unilateral V-Y RAF and included the digital neurovascular bundle to the flap [23].

Sungur et al. elevated bilateral V-Y RAF from the volar side of the finger to reconstruct seven fingertip amputations. Skin pedicles of the flaps were on the lateral sides of the finger, and the flaps were elevated above the paratenon of the flexor tendon by including the neurovascular bundle to the flap [23].

Elshahat used unilateral V-Y RAF to cover two femoral, one knee, one plantar, and one fingertip defects and eight trochanteric pressure sores [10]. Sowerby et al. reconstructed 21 lower and 18 upper extremity defects with bilateral V-Y RAF [19].

Discussion

Local flaps have an excellent color match that no other flap can compete with. Local flap surgery is easier and faster than distant and free flaps. However, designing a local flap is much harder than the surgery. While planning the flap, a surgeon must think about the viability of the flap, the donor area of the flap, and the shape of the final scar. For random flaps, there is a width-to-length ratio ranging from 1:2 to 1:4 depending on the region of the body [34]. Although, with the increasing knowledge of perforator vessels, it is often possible to design a local flap based on a perforator artery in any region of the body. As plastic surgeons, we all desire to close the donor area of a flap primarily. This is why flaps are harvested from the regions where there is a skin laxity. What happens if the defect is on a tight area where there is no known artery? V-Y RAF is the saver. That flap was performed on all the regions of the body by several authors and none of the authors reported flap loss or any dehiscence or skin slough that resulted with a second surgery [10, 12–14, 18–20]. In order to obtain inconspicuous scars, suture lines are disguised in the RSTLs or among the connection margins of different structures such as the nose and the cheek or the forehead and the hairline. Despite the fact that it is not always possible to hide the scar, all the authors were satisfied with the final scar of that flap. Zhi-guo et al.'s article was the only article that executed a questionnaire about the scar and none of the patients complained about the color match [17]. Hypoesthesia is another big problem for flaps, but it is proved that V-Y RAF is a sensate flap [13, 15, 20, 23–25]. In addition, it is possible to elevate this flap either cutaneously or fasciocutaneously or musculocutaneously [35–37]. It means that both a defect of excised nevus and a deep cavity of a decubitus ulcer can be covered by the same flap but in different thickness.

All these properties make this flap very versatile, but there is still no consensus on the dimensions of the flap. While reproducibility is very important in science, we brought the geometrical formula of this flap to the discussion in order to allow surgeons, mostly the inexperienced ones, to design their flaps without hesitation. Although medicine is not only a science, surgeons can show their artistic skills by adapting this formula according to the elasticity and redundancy of the patient's skin and to the shape and place of the defect.

Conclusion

Both senior and junior surgeons can perform this flap on any region of the body with confidence. Despite its frequent use all over the world, V-Y RAF does not have a special name in the nomenclature yet.

Acknowledgment We hereby thank Nihal Sulkalar Dölen for helping us with her drawings.

Conflict of interest None.

Ethical standards The manuscript does not contain clinical studies or patient data.

References

1. Nasir AR, Brenner SA (2012) Think small: nanotechnology for plastic surgeons. Ann Plast Surg 69(5):580–587
2. Dorafshar AH, Franczyk M, Gottlieb LJ, Wroblewski KE, Lohman RF (2012) A prospective randomized trial comparing subatmospheric wound therapy with a sealed gauze dressing and the standard vacuum- assisted closure device. Ann Plast Surg 69(1):79–84
3. Kang GC, Por YC, Tan BK (2010) In vivo tissue engineering over wounds with exposed bone and tendon: autologous dermal grafting and vacuum- assisted closure. Ann Plast Surg 65(1):70–73
4. Ibrahim AM, Gerstle TL, Rabie AN, Song YA, Melik R, Han J, Lin SJ (2012) Nanotechnology in plastic surgery. Plast Reconstr Surg 130(6):879e–887e
5. Lineaweaver WC (2009) Problem analysis in reconstructive surgery: up and beyond the reconstructive ladders. In: Wei, FC and Mardini, S (edn) Flaps and reconstructive surgery. Saunders; pp. 3–6
6. Roehl KR, Mahabir RC (2013) A practical guide to free tissue transfer. Plast Reconstr Surg 132(1):147e–158e
7. Thornton JF, G AA (2004) Skin grafts and skin substitutes and principles of flaps. Sel Read Plast Surg 10
8. Argamaso RV (1974) V-Y-S-plasty for closure of a round defect. Plast Reconstr Surg 53(1):99–101
9. Emmett AJ (1977) The closure of defects by using adjacent triangular flaps with subcutaneous pedicles. Plast Reconstr Surg 59(1):45–52
10. Elshahat A (2012) The versatility of the hatchet flap in soft tissue reconstruction and a proposed new classification. Eur J Plast Surg 35: 351–357

11. Abd El-Rahim MK (2012) A: V-Y-C and V-Y-S plasties and a simple algorithm for correction of acquired alopecia. Eur J Plast Surg 35: 781–786
12. Demir Z, Velidedeoglu H, Celebioglu S (2003) V-Y-S plasty for scalp defects. Plast Reconstr Surg 112(4):1054–1058
13. Gurunluoglu R, Shafighi M, Williams SA, Glasgow M (2012) Reconstruction of large supra-eyebrow and forehead defects using the hatchet flap principle and sparing sensory nerve branches. Ann Plast Surg 68(1):37–42
14. Gurunluoglu R, Williams SA, Olsen A (2014) Reconstructive outcomes analysis of lower eyelid and infraorbital skin defects using 2 hatchet flaps: a 6-year experience. Ann Plast Surg 72(6):657–662
15. Fernandez-Calderon M, Casado-Sanchez C, Cabrera-Sanchez E, Casado-Perez C (2012) Versatility of hatchet flaps for the repair of scalp defects. Actas Dermosifiliogr 103(7):629–631
16. Sheridan AT, Humzah D (2000) V-Y-S-plasty closure of circular defects. Australas J Dermatol 41(4):260–261
17. Zhi-guo W, Quan-chen X, Rui-xia K, Zhen-yu C, Ran H (2012) Principles of hatchet-skin flap for repair of tissue defects on the cheek. Aesthetic Plast Surg 36(1):163–168
18. Borman H, Maral T (2002) The gluteal fasciocutaneous rotation-advancement flap with V-Y closure in the management of sacral pressure sores. Plast Reconstr Surg 109(7):2325–2329
19. Sowerby LJ, Taylor SM, Moore CC (2010) The double hatchet flap: a workhorse in head and neck local flap reconstruction. Arch Facial Plast Surg 12(3):198–201
20. Sungur N, Kankaya Y, Gursoy K, Dolen UC, Kocer U (2013) A local flap that never disappoints: V-Y rotation advancement flap. Ann Plast Surg 71(5):575–580
21. Lane JC, Swan MC, Cassell OC (2013) Closure of the radial forearm donor site using a local hatchet flap: analysis of 45 consecutive cases. Ann Plast Surg 70(3):308–312
22. Kuwahara M, Yurugi S, Mashiba K, Iioka H, Niitsuma K, Noda T, Manago E (2012) Aesthetic reconstruction of a defect in the skin of the upper lip using a hatchet flap. J Plast Surg Hand Surg 46(2):80–84
23. Sungur N, Kankaya Y, Yildiz K, Dolen UC, Kocer U (2012) Bilateral V-Y rotation advancement flap for fingertip amputations. Hand 7(1):79–85
24. Sungur N, Kocer U, Uysal A, Arslan C, Cologlu H, Ulusoy G (2006) V-Y rotation advancement fasciocutaneous flap for excisional defects of pilonidal sinus. Plast Reconstr Surg 117(7):2448–2454
25. Tuncali D, Barutcu AY, Gokrem S, Terzioglu A, Aslan G (2006) The hatchet flap for reconstruction of fingertip amputations. Plast Reconstr Surg 117(6):1933–1939
26. Baron JL, Reynaud JP, Gary-Bobo A, Maya M (1990) Specificity of hatchet flaps in the laterofacial region. Ann Chir Plast Esthet 35(1): 47–52
27. Reynaud JP (1983) Hatchet flap for the repair of cutaneous excisions on the nose. Apropos of 30 cases. Ann Chir Plast Esthet 28(4):369–375
28. Sharma RK, Mishra S, Sharma S (2010) Multiple V-Y advancement and rotation flaps for a large cheek defect. Dermatol Surg 36(10): 1605–1609
29. Tremblay JF, Bernstein SC (2001) Hatchet flap. Dermatol Surg 27(12):1049–1051
30. Pan Y, Ai Y, Li H, Guo S (2004) Local hatchet flap for facial skin defects reconstruction in special areas. Dermatol Surg 30(9):1256–1260
31. Makiguchi T, Yokoo S, Miyazaki H, Soda T, Terashi H (2013) Combined bilateral hatchet and nasolabial advancement flaps for a large defect of the lower lip. J Craniofac Surg 24(6):e588–e590
32. Yu TC, Desciak EB, Eliezri YD (2006) Bilateral hatchet flaps. Dermatol Surg 32(10):1279–1282
33. Schwabegger AH, DelFrari B, Apprich C (2006) Pedicled deltoid hatchet flap for treatment of pressure sore at the shoulder. Eur J Plast Surg 28:534–536
34. Mathes SJ, Hansen SL (2006) Flap classification and applications. In: Mathes SJ (ed) Plastic surgery, volume 1, Secondth edn. Saunders Elsevier, Philadelphia, pp 365–481
35. Josvay J, Sashegyi M, Kelemen P, Donath A (2005) Clinical experience with the hatchet-shaped gluteus maximus musculocutaneous flap. Ann Plast Surg 55(2):179–182
36. Li CC, Chang SC, Fu JP, Tzeng YS, Wang CH, Chen TM, Chen SG (2013) Comparison of hatchet-shaped tensor fascia lata flap and pedicle anterior lateral thigh flap for treatment of trochanteric sores: a retrospective analysis of 48 patients. Ann Plast Surg 71(6):659–663
37. Quillot M, Lodde JP, Pegorier O, Reynaud JP, Cormerais A (1994) A variant of island flaps for the covering of pressure sores: the hatchet flap. Apropos of 31 cases. Ann Chir Plast Esthet 39(4):469–472

View publication stats